

Case Report



Ayurvedic management of a chronic non-responsive case of Charmakhya Kushta (Lichen Simplex Chronicus): A Case Report

[1Praveen.N. Bhirdi](#), [2*Rekha.B.Pattar](#), [3Keertan M S](#), [4Shivayogi N](#), [5Sangeeta S H](#)

ABSTRACT:

Introduction: In Ayurveda *Charmakhya* is one among the type of *Kshudra Kushta* in which there will *Twak vaivarnyata* like *Hasti Charmavat*, *Khara Sparsha*, *kandu* and *Raga* are seen. This condition in contemporary science can be compared with Lichen simplex Chronicus based on its signs and symptoms. *Charmakhya* is mainly caused by vitiation of *Tridosha* mainly *Vata* and *Kapha dosha* along with this there will be vitiation of *Rasa*, *Rakta* and *Mamsa dhatu*. Ayurveda treatment mainly helps in treating the disease from root. **Clinical findings:** A 33-year-old female visited to Rajashekharaiyah Ayurvedic hospital, Bangalore with OPD number 4326 on 16th April 2025, complaints of *tvak vaivarnya*, specially over bilateral Ankle joint. Accompanied by *Kandu* (itching), *Raga* (redness), and *Khara Sparsha* (rough texture). The symptoms developed gradually and were unresponsive to previous standard treatments. **Intervention:** Ayurvedic treatment included *Deepana-Pachana* (strengthening of the stomach), *Snehapana* (oleation), followed by *Abhyanga* (body massage), *Parisheka* (pouring), *Virechana* (purgation), *Matra basti* and *Shamana Chikitsa* (palliative treatment). **Outcome:** The patient attained *Madhyama Shuddhi* of *Virechana*; after *Virechana* and *Shamana chikitsa* noticeable improvement in symptoms and a decrease in disease severity. Itching decreased from severe to mild, lichenification markedly reduced, erythema, scaling and pigmentation showed gradual improvement's, this indicates effective *twacha gata dosha* and *kapha-vata dosha prashamana*. **Conclusion:** Following 26 days of *Shodhana* and 60 days of *Shamana chikitsa*, the patient with chronic, non-responsive *Charmakhya* (Lichen Simplex Chronicus) shown a marked improvement. When *Virechana*, *Matra Basti* and *Shamanoushadi* were used together, the underlying *dosha* imbalance was successfully corrected without any side effects. These findings imply that Ayurvedic treatments could aid in the creation of more successful treatment plans for these kinds of long-term skin conditions.

KEYWORDS: *Charmakhya kushta*, Lichen simplex chronicus, *Snehapana*, *Virechana*, *Shamana*, Case report.

RECEIVED ON:

08-10-2025

REVISED ON:

07-11-2025; 26-11-2025

ACCEPTED ON:

28-11-2025

Access This Article Online:

Quick Response Code:



Website Link:

<https://jahm.co.in>

DOI Link:

<https://doi.org/10.70066/jahm.v13i11.2381>

Corresponding Author Email:

rekhapattar6@gmail.com

CITE THIS ARTICLE AS

Praveen. N. Bhirdi, Rekha.B.Pattar, Keertan M S, Shivayogi N, Sangeeta S H. Ayurvedic management of a chronic non-responsive case of *Charmakhya Kushta* (Lichen Simplex Chronicus): A case report. *Journal of Ayurveda and Holistic Medicine (JAHM)*.2025;13(11):79-86

1. INTRODUCTION

Twak (skin) is the *Upadhatu* (secondary tissue) of *Mamsa Dhatu* (muscle tissue). It performs various essential functions of the body and it is the *sparshanendriya adhishtana* (tactile organ). *Kushta* is defined as '*Kushnati Vapu Iti Kushta*' means that which makes the body unpleasant to look. [1] It is one of the *santarpana janya vyadhi* (diseases caused by over nourishment) which has *bahudoshavastha* (excessive doshic imbalances). *Kushta* is manifested due to the vitiation of *Sapta dushya* (vitiating factors) such as *Vata*, *Pitta*, *Kapha*, *Lasika* (lymph), *Twacha*, *Rakta* (blood) and *Mamsa*. Based on the severity it is broadly classified as *mahakushta* (major skin diseases) and *kshudra kushta* (minor skin diseases). [2] According to *Acharya Charaka charmakhya* is one of the *kshudra kushta*, characterized by patchy abnormal increase of thickness of skin which resembles the skin of *Hasthi*. *Rasa*, *Rakta* and *Mamsa dhatu* are majorly involved in the *samprapti*. [3] As per contemporary system these symptoms resemble the clinical condition of lichen simplex chronicus. It has the prevalence rate of 10-12%, majorly affects middle aged people more in females than in males at a ratio of 2:1. [4] Lichen simplex chronicus is defined as a common form of chronic neurodermatitis that presents as dry, patchy areas of skin that are scaly and thick. The hypertrophic epidermis generally seen, is typically the result of habitual scratching or rubbing of a specific area of the skin. [5] The plaques form as a result of constant and repeated scratching of specific areas. [6] Contemporary management of *Charmakhya* (lichen

simplex chronicus) includes external application of topical corticosteroid ointments, lotions, antihistamines and antibiotics. [7] In contrast Ayurveda will provide Individualized, comprehensive and root cause - oriented treatment strategies that includes *Panchakarma* (five detoxifying procedures) therapies, internal medicines, lifestyle and diet modification. *Panchakarmas* are the main Ayurveda therapeutic procedures includes *Abhyanga* (Body massage), *Swedana* (sudation therapy), *Snehapana* (oleation therapy) & *Virechana* (purgative therapy) which are known to pacify imbalanced *pitta dosha* which is mainly involved in *Charmakhya*. [8] This case study presents the clinical experience in managing the patient with *Charmakhya* a skin condition through Ayurveda line of management, after completion of *Panchakarma* itching sensation and redness reduced & thickness of lesions reduced, even though it is non-responsive chronic condition case to conventional therapies, *Panchakarma* plays major role in successful outcomes. It results in significant symptomatic and functional improvement. It aims to highlights the potentials of holistic approach in the management of Skin disorders in particularly *Charmakhya* (lichen simplex chronicus).

2. CASE REPORT

A 33-year-old female patient presented to the OPD of Rajashekharaiyah Ayurvedic Hospital, Bangalore, on 16/04/2025 (OPD No: 4326), with complaints of reddish-black, thick, lichenified plaques over both ankle joints associated with severe itching, burning sensation and intermittent serous discharge for the

past 7–8 years, which began as mild itching around the ankles and gradually progressed due to continuous scratching, leading to erythema, skin thickening and later well-defined lichenified lesions. The condition worsened becoming chronic and resistant to conventional therapy. The patient had been using allopathic treatment for nearly six years, including topical corticosteroids and emollients, which provided only temporary relief; recurrence and worsening of itching and thickness occurred upon discontinuation.

Clinical findings: According to *Ayurveda*, *prakruti* of the patient was *vata-kaphaja prakruti* and *dosha* in *vyadhi awastha* was *vata-kapha pradhana tridosha* and

dushya's are *twak, rakta, mamsa* and *lasika*. On local examination observed findings such as, site of lesion – bilateral ankle joints, number of lesion – 4, type of lesion – plaque with irregular border, measurement – 12 cm length and 6 cm width approximately, itching – present, discharge – present, colour – reddish black, scaling and thickness – present, 0.6mm, texture of lesion – rough, leathery and scaly lesion.

Diagnostic assessment : Based on the clinical findings, diagnosis was established as lichen simplex chronicus as per modern science and lakshana like *tvak vaivarnyata, kandu, raaga* and *kina khara Sparsha* etc. the case was diagnosed as *Charmakhya Kushta*.

Table no : 1 Differential diagnosis :

For <i>Charmakhya Kushta</i> :		
Sl.no	Condition	Clinical Features
1.	<i>Dadru</i>	<i>Mandala, kandu</i> and <i>rakta varna</i> (circular lesions with itching and redness)
2.	<i>Vicharchika</i>	<i>Srava, peedaka</i> and <i>kandu</i> (discharge, lesions and itchy) due to scratching.
3.	<i>Ekakustha</i>	<i>Matsyashakalopamam</i> (dry lesions resembling fish scales), non-itchy.
For Lichen Simplex Chronicus :		
1.	Psoriasis	Well demarcated erythematous plaques with silvery scales; common in knees, elbows & scalp.
2.	Lichen planus	Flat-topped, violaceous papules with Wickham's striae; often on wrist, ankles and oral mucosa.
3.	Contact dermatitis	Erythema, vesiculation, crusting in areas of exposure; may become lichenified if chronic.
4.	Chronic atopic dermatitis	Chronic relapsing eczema with lichenification due to scratching; usually widespread with history of atopy.

Table no : 2 Laboratory Investigation

Sl.No	Investigation	BT	AT
1	CRP	20 mg/dl	8 mg/dl
2	ESR	56mm/hr	24mm/hr
3	CBC	Increased count of Lymphocyte and neutrophils	Within normal limit

Time line for intervention

Table no: 3 Treatment schedule

16-04-2025 to 18-04-2025	<i>Chitrakadi Vati</i> <i>Agnitundi vati</i>	1-1-1 before food
19-04-2025 to 23-04-2025	<i>Snehapana</i> with <i>Mahatiktaka Ghrita</i> Day 01– 30ml	<i>Ganji</i> when felt hungry,

	Day 02 – 60ml Day 03 – 90ml Day 04 – 120ml Day 05- 150ml	Night - <i>Kichadi</i>
24-04-2025 to 25-04-2025	<i>Sarvanga Abhyanga</i> with <i>Jatyadi taila</i> followed by <i>SarvangaTriphala Parisheka</i> .	Diet: Morning and Afternoon - Rava idli / rice rasam. Night: Dal kichadi
26-04-2025	<i>Sarvanga Abhyanga</i> with <i>Jatyadi taila</i> followed by <i>SarvangaTriphala Parisheka</i> . <i>Virechana</i> with <i>Trivruth leha</i> – 70gm and <i>Triphala</i> <i>kashaya</i> 100ml & 5days <i>samsarjana krama</i> advised	Taken <i>Ganji</i> once felt hungry.
01-05-2025 to 05-05-2025	<i>Lepa</i> with <i>Dashanga Lepa</i> and <i>Nimba Choorna</i> - quantity sufficient.	<i>Samanya</i> <i>bhojana</i> (<i>Pathya</i> <i>ahara</i>)
06-05-2025 to 12-05-2025	<i>Matra basti</i> with <i>Panchatikta ghrta</i>	50ml for 7days
<i>Shamanoushadi</i>		
Medicine	Dose	Duration
<i>Arogyavard</i> <i>hini Vati</i>	1-0-1 After food	60 days
<i>Maha</i> <i>Manjistadi</i> <i>Kashaya</i>	20ml-0-20ml with 20ml of warm water After food	60 days
<i>Triphala</i> <i>choorna</i>	0-0-1tsp with warm water After food	60 days
<i>Panchavalka</i>	For <i>Avagaha sweda</i>	60 days

<i>la kwata</i> <i>choorna</i>	(20minutes)	
<i>Pachanimba</i> <i>choorna</i>	<i>Lepa</i> for External application	60 days
<i>Jatyadi taila</i>	External Application	60 days

On the fifth Day of *Snehapana*, *Sneha Siddhi Lakshana* were seen, which included *Sneha dweshi* characteristics, *Sneha twacha*, *Sneha yukta mala*, and lightness of the body. During *Virechana Karma*, the patient experienced 22 *Vegas*. Classical *Lingaki* symptoms, including body lightness, less itching, and thinner lesions, were noted following *Virechana*. According to traditional standards, *Samsarjana Krama* was administered for five days after *Virechana Karma*. After that, *Dashanga Lepa* and *Nimba Choorna* were used to perform *Lepa Karma* and *Panchavalkala Kwatha* was used for *Avagaha Sweda* for 20 minutes every Day. After that, *Panchatikta Ghrta Matra Basti* were given for seven days. Patient adhered to treatment well and regular reminders are given for daily intake of medicines.

***Pathya* (wholesome diet and regimen)**

Regular home - made food, *koshna jala* (Luke warm water), *mudgha yusha* (green gram soup) & *pranayama* (breathing exercise).

***Apathya* (unwholesome diet and regimen)**

Curd, nonveg specially fish, junk food like lays, pups, *diwaswapna* (Day sleep), scratching.

Table no: 4 Assessment criteria

Assessment Criteria	Parameters	Gradation	
		BT	AT
Lichenification (<i>Hasti Charma</i>) – Thickness of skin	Mild thickness	++ (4 inch)	+ (2 inch)
	Moderate	+	
	Sever		
<i>Khara sprasha</i> (excoriation)	Mild	+++	Absent
	Moderate	++	
	Sever		
<i>Kandu</i> (Itching)	Mild	+++	+
	Moderate		
	Sever		
<i>Twak vaivarnyata</i> (<i>Shyava -Aruna varna</i>)	Mild Brownish colour	+++	+
	Moderate	+++	+
	Sever	++	

Follow-up and outcomes : The Patient was instructed for follow up on a regular basis after *Virechana* and the changes were evaluated; there were no any adverse events observed during & after treatment. There was a significant improvement in symptoms such as dryness of the skin, roughness of the skin, discolouration and pruritus.

Figure- 01

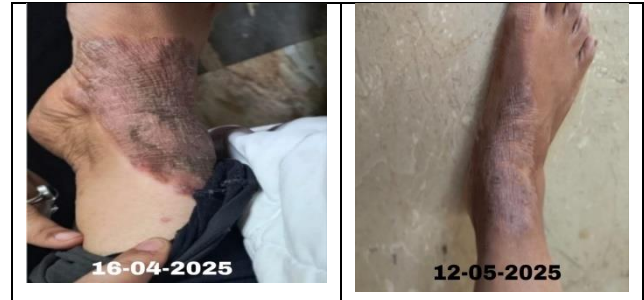
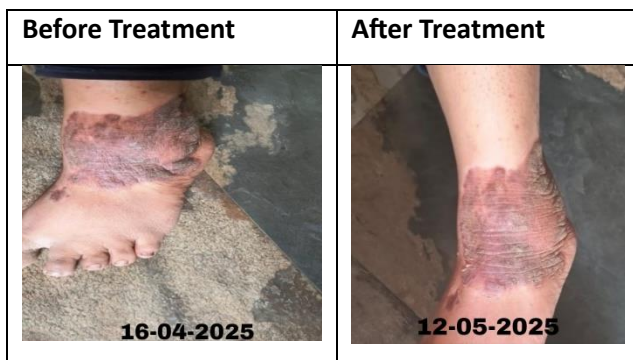
Figure-01: Images of before and after treatment

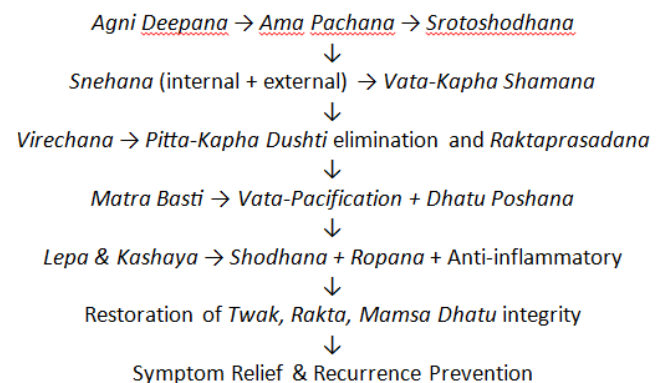
3. RESULT

After completion of *Panchakarma* itching sensation and redness reduced & thickness of lesions reduced.

4. DISCUSSION

Lichen simplex chronicus is a chronic skin condition caused by repetitive scratching and rubbing which leads to thick leathery itchy skin lesions, it is not contagious disease. [9] The Lichen simplex chronicus is similar to *Charmakhya Kushta* with symptoms such as *Kharasparsha*, *Kandu*, *Hasti charmavat*, which is mainly caused due to vitiation of *Vata* and *Kapha dosha* along with these *dosha's Rasa, Rakta* and *mamsa dhatu* was involved. By careful understanding of involved *dosha's, dushya's* and stage of disease we can treat this disease by adopting *Panchakarma* therapies like *Snehapana, Abhyanga parisheka* and *Virechana, Lepa, avagaha sweda* and *Matra basti*.

Mode of Action :



Snehapana (Mahatiktaka Ghrita) : Mahatiktaka ghrita contains ingredients like Patola, Haridra, Musta, Aragvada, Triphala, Nimba, Katuka, Amruta, Kiratatikta etc. all these drugs are Tikta rasatmaka, ushna viryatmaka, Rakta shodaka which mainly acts on vitiated Kapha dosha and does the Rakta prasadhana, which helps in reducing the symptoms like Kandu and Kharasprashata. [10] Rakta is the main dhatu involved in this disease and tikta rasa will help in rakta shodhana and corrects both jataragni and dhatvagni which is hampered in this disease.

Virechana (Trivrut Lehya): Virechana Dravya's are having the qualities like Ushna, Tikshna, Vyavayi and Vikasi Guna helps the Virechana Dravya taking entry into Sthoola and Sukshma Dhamani and does the Sroto Shodana and expelling the vitiated Dosha's also clears sroto sanga which is the main pathology in Charmakhya kushta. As a result of earlier Snehana Karma, the liquefied Doshas are disintegrated from their channels, these disintegrated Doshas move through the fine Srotas, making their way to the Koshtha before reaching the Amashaya. [11]

Lepa: In this case lepa was done by using the powders like Dashanga lepa and nimba. Dashanga lepa has 10 ingredients in it such as Yasti madhu, ushira, Chandana, kushta, Sirisha, Tagara, Ela, Haridra, Jatamamsi, Daruharidra. All these ingredients are acts as Kushtagna and along with Dashanga lepa, Nimba choorna enhanced the efficacy of Dashanga Lepa in treating Kushta. [12]

Avagaha Sweda (Panchavalkala kwata): Panchavalkala kwata plays vital role in management of kushta mainly

lesions with inflammation, itching and microbial infection because all these panchavalkala drugs are mainly having Kashaya Rasa and has properties like Shodhana and Ropana hence it can be caused in treating Charmakhya.

Basti (Matra basti with Panchatiktaka Ghrita) : Sneha Basti is best for treating Vata dosha and it does not increase the kapha dosha, Panchatiktaka ghrita is best in treating kushta, hence Panchatiktaka ghrita Matra Basti helped in treating Charmakya kushta. [13]

Arogyavardhini Vati: In Arogyavardhini vati Katuki as a main ingredient along with katuki, it has Triphala, Suddha Parada, Gandaka, Nimba and shilajatu which mainly acts as Rakta prasadhana, tissue rejuvenation and balances Vitiated Pitta and medha hence helps in treating Charmakhya. [14]

Jatyadi Taila: Jatyadi taila has key ingredients like Jati, nimba, Haridra, daruharidra, Manjistha, Patola, Karanja and tila taila most of these drugs are Tikta and Kashaya rasa pradhana acts on Rakta and Twacha and all ingredients of Jatyadi taila are Vrunda ropana and Kushtagna drugs and acts mainly on Kapha Rakta and vata hence can be used in Charmakhya.

Maha Manjistadi Kashaya: Maha Manjistadi Kashaya is well known Ayurveda formulation mainly used as Rakta shodaka, anti-inflammatory, also acts as immune modulatory due to which it is main drug of choice in Kushta. [15]

Limitations : Since this is a single case study, findings cannot be generalized, the follow-up period was short (2months), so further research involving a larger number of patients is recommended to validate the

efficacy & safety Ayurvedic treatment modalities with no adverse reactions.

5. CONCLUSION

The present case was treated with both *Shodananga* (26 days) and *Shamananga chikitsa* for period of 60 days (follow-up period) and got remarkable result. As this *Charmakhya* (Lichen Simplex Chronicus) is chronic non-responsive case since past 7-8 years, temporarily symptoms got relief from allopathic treatment, but prolonged use of allopathic treatment worsened the condition, so *shodana* is needed to treat the disease from the root and as *Virechana* is ideal to *Pitta dosha Vikara's*, *matrabasti* is best for *vata dosha* simultaneously balances the *kapha dosha*, along with *Shamanoushadi* gave remarkable result in this present case. There were no any adverse effects throughout treatment including follow-up on (12/07/2025). Further research on use Ayurveda Intervention in treating *Charmakhya Kushta* can helps in building different and effective treatment protocol in treating such disorders.

Declaration of Patient Consent – The authors confirm that they have acquired a patient consent form, in which the patient or caregiver has granted permission for the publication of the case, including accompanying images and other clinical details, in the journal. The patient or caregiver acknowledges that their name and initials will not be disclosed, and sincere attempts will be undertaken to safeguard their identity. However, complete anonymity cannot be assured.

Patient perspective - Initially patient had severe itching sensation, serous discharge, lichenified lesions on affected site (bilateral ankle joints), she was anxious about scratching in social gathering. As treatment progressed symptoms were relieved. After follow up the patient was happy with the treatment because it was easy, safe, and made life better.

Authors Details:

¹Associate Professor, Dept of Samhita Siddhanta, KAHER'S Shri B M Kankanawadi Ayurveda Mahavidyalaya, Shahapur, Belagavi, Karnataka

^{2*}Assistant Professor Department of Koumarbhritya, Sri Paripoorna Sanathana Ayurveda Medical college, Hospital & Research centre, Bangalore, Karnataka

³Professor, Dept of RogaNidana, KAHER'S Shri B M Kankanawadi Ayurveda Mahavidyalaya, Shahapur, Belagavi, Karnataka

⁴PG Scholar, Dept of RogaNidana, KAHER'S Shri B M Kankanawadi Ayurveda Mahavidyalaya, Shahapur, Belagavi, Karnataka

⁵PG Scholar Department of Kayachikitsa, Karnataka Ayurveda Medical college and Hospital, Mangalore, Karnataka

Authors Contribution:

Conceptualization and clinical management: PNB, RBP,

Data collection and literature search: KMS, PNB, SN,

Writing – original draft: RBP, PNB, KMS

Reviewing & editing: PB, RP, KMS, SSH

Approval of final manuscript: All authors

Acknowledgements - We appreciate the support and guidance provided by our colleagues and institutions throughout the research process.

Declaration of Generative AI

The authors declare this manuscript was written without the use of generative artificial intelligence tools. All the content, including text generation, data analysis and references was developed and reviewed by the author without assistance from AI technologies.

Conflict of Interest – The authors declare no conflicts of interest.

Source of Support – The authors declare no source of support.

Additional Information:

Authors can order reprints (print copies) of their articles by visiting:

<https://www.akinik.com/products/2281/journal-of-ayurveda-and-holistic-medicine-jahm>

Publisher's Note:

Atreya Ayurveda Publications remains neutral with regard to jurisdictional claims in published maps, institutional affiliations, and territorial designations. The publisher does not take any position concerning legal status of countries, territories, or borders shown on maps or mentioned in institutional affiliations.

REFERENCES:

1. Yadavaji Trikamaji [editor]. Commentary: Ayurveda Deepika of Chakrapani on Charaka Samhita of Charaka, Chikitsa Sthana, chapter 7, verse no.3, 2nd edition, Varanasi; Chowkhambha Sanskrit Sansthan;2017;446
2. Abhilesh VS, Prathibha CKB, Anandaraman PVS. Management of Erythrodermic Psoriasis through Ayurveda - A Case Report. Perm J. 2021 Aug 11;25:20.221. <https://doi.org/10.7812/TPP/20.221>
3. Yadavaji Trikamaji [editor]. Commentary: Ayurveda Deepika of Chakrapani on Charaka Samhita of Charaka, Chikitsa Sthana, chapter 7, verse no.21, 2nd edition, Varanasi; Chowkhambha Sanskrit Sansthan;2017 ;451
4. Lotti T, Buggiani G, Prignano F. Prurigo nodularis and lichen simplex chronicus. Dermatologic Therapy. 2008;21:42-46 . <https://doi.org/10.1111/j.1529-8019.2008.00168.x>
5. Borghi A, Virgili A, Corazza M. Dermoscopy of Inflammatory Genital Diseases: Practical Insights. Dermatol Clin. 2018 Oct;36(4):451-461. <https://doi.org/10.1016/j.det.2018.05.013>
6. Muylaert BPB, Borges MT, Michalany AO, Scuotto CRC. Lichen simplex chronicus on the scalp: exuberant clinical, dermoscopic, and histopathological findings. An Bras Dermatol. 2018 Jan-Feb;93(1):108-110. <http://dx.doi.org/10.1590/abd1806-4841.20186493>
7. Fruchter R, Melnick L, Pomeranz MK. Lichenoid vulvar disease: A review. Int J Womens Dermatol. 2017 Mar;3(1):58-64 <https://doi.org/10.1016/j.ijwd.2017.02.017>
8. Yadavaji Trikamaji [editor]. Commentary: Ayurveda Deepika of Chakrapani on Charaka Samhita of Charaka, Chikitsa Sthana, chapter 7, verse no.40, 2nd edition, Varanasi; Chowkhambha Sanskrit Sansthan;2017;452
9. Muylaert BPB, Borges MT, Michalany AO, Scuotto CRC. Lichen simplex chronicus on the scalp: exuberant clinical, dermoscopic, and histopathological findings. An Bras Dermatol. 2018 Jan-Feb;93(1):108-110. <http://dx.doi.org/10.1590/abd1806-4841.20186493>
10. Yadavaji Trikamaji [editor]. Commentary: Ayurveda Deepika of Chakrapani on Charaka Samhita of Charaka, Chikitsa Sthana, chapter 7, verse no.16, 2nd edition, Varanasi; Chowkhambha Sanskrit Sansthan;2017;451
11. Rais A, Bhatted S. Clinical study to evaluate the effect of Virechanakarma on serum electrolytes. AYU. 2013 Oct-Dec;34(4):379-82. <https://doi.org/10.4103/0974-8520.127719>
12. Neha Meena, Vashishtha, Vidhu Singh, Rajendra Prasad Sharma, Sakhitha K.S. Review on dashanga lepa-An anti-inflammatory formulation. J of Ayurveda and Hol Med(JAHM). 2023 Sept;11(9):129-138. <https://doi.org/10.70066/jahm.v11i9.1058>
13. Yadavaji Trikamaji [editor]. Commentary: Ayurveda Deepika of Chakrapani on Charaka Samhita of Charaka, Chikitsa Sthana, chapter 7, verse no.21, 2nd edition, Varanasi; Chowkhambha Sanskrit Sansthan;2017;451
14. K Koundal, H Vyas. Ayurvedic approach in the management of Charmakhya Kushta w.s.r. to Lichen Simplex Chronicus (Neurodermatitis) - A Case Report. J Ayu Int Med Sci. 2025 Aug;10(8):274-82. <https://doi.org/10.21760/jaims.10.8.46>
15. Madenhalli K, Bhirdi P, Namastemath S, Deepika G. S. Ayurvedic Approach to Managing Kitibha Kushta (Guttate Psoriasis): A Case Study. J of Ayurveda and Hol Med(JAHM). 2025. Sept;13(8):130-136. <https://doi.org/10.70066/jahm.v13i8.2223>