

## Case Report



### Analgesic and Anti-Inflammatory Effects of *Jalaukaavcharan* (Leech Therapy) in *Raktaj Arsha* (Thrombosed Hemorrhoids): A case report based Biomarker Analysis

<sup>1</sup>\*Santosh Y M, <sup>2</sup>Raj Joshi, <sup>3</sup>Ujjwal Gupta

#### ABSTRACT:

**Background:** *Arshas* (Hemorrhoids) is a commonly prevalent ano-rectal disease. Thrombosis is acute complication that occurs in hemorrhoids due to increased venous pressure, causing venous rupture and clot formation which requires immediate treatment, but there is a problem in selecting conservative or surgical management as both have their drawbacks. *Raktaavsechana* (bloodletting) is a procedure mentioned by *Acharya Vagbhata* for managing *Arshas* with this complication. **Clinical Findings:** A 38 year old patient came to our OPD having complaints of severe pain in anal region along with tender mass and discomfort in anal region. He was unable to pass flatus for the past 3 days. A local examination of perianal region showed a single reddish purple, dark, congested, tender and firm mass extending from 6 to 7 o'clock position. **Intervention:** After the examination and history, the case was diagnosed as *Raktaj Arsha* (EE-3.7) as per *Ayurveda* and Thrombosed External Hemorrhoids (TEH) according to modern science. Patient was managed by *Jalaukaavcharan* (Leech therapy), followed by *Haridra churna* (Curcuma longa powder) bandaging. **Outcome:** Clinically patient showed significant reduction in VAS, VDS pain Scores levels to 0/10 by the 3<sup>rd</sup> day, and biomarker i.e, IL6 levels from 15.462 pg/ml to 0 pg/ml. **Conclusion:** In the present case, *Jalaukaavcharan* has shown crucial outcomes as it exhibited analgesic and anti-inflammatory activity which are observed, as clinical symptoms were resolved as well as biomarker IL6 levels reduced, providing evidence and its use in the current ano-rectal care as a potential noninvasive procedure for the integration in the treatment of painful ano-rectal disease (TEH). Hence application of *Jalauka* (Leech) had analgesic and anti-inflammatory effects.

**KEYWORDS:** *Arshas*, Haemorrhoids, *Jalaukaavcharan*, Leech therapy, *Raktaavsechana*, TEH, Case Report.

RECEIVED ON:

27-08-2025

REVISED ON:

25-10-2025

ACCEPTED ON:

03-11-2025

Access This Article Online:

Quick Response Code:



Website Link:

<https://jahm.co.in>

DOI Link:


<https://doi.org/10.70066/jahm.v13i10.2308>

Corresponding Author Email:

[drmysantosh@gmail.com](mailto:drmysantosh@gmail.com)

CITE THIS ARTICLE AS

Santosh Y M, Raj Joshi, Ujjwal Gupta. Analgesic and Anti-Inflammatory Effects of *Jalaukaavcharan* (Leech Therapy) in *Raktaj Arsha* (Thrombosed Hemorrhoids): A case report based Biomarker Analysis. *Journal of Ayurveda and Holistic Medicine (JAHM)*.2025;13(10):118-129



## 1. INTRODUCTION

A hemorrhoid is a common anorectal condition with a prevalence rate of 11% in India. It is correlated to *Arshas* (Hemorrhoids) in *Ayurveda*, having a Global prevalence rate of 5% (over 18 years of age), 50% (over 50 years of age). About 90% of population suffers with hemorrhoids at least once in their lifetime in that 10% undergoes surgery. [1] Thrombosis is a complication that occurs in hemorrhoids due to increase in venous pressure, causing venous rupture leading to clot formation. It is an acute complication which requires immediate treatment, but there is a problem in selecting conservative or surgical management, as conservative management is associated with slow recovery and higher recurrence whereas surgical management has contraindications, comorbidities, or risk of complications. [2] So, effective minimal noninvasive alternatives are required for the management of Thrombosed External Hemorrhoids (TEH). TEH can be correlated to *Raktaj Arsha* (*Arśas* due to *Rakta*), which is described in classical texts with symptoms like *Vatapararoha*, *Vidrum*, *Kakantikafala Sadrasani*, (pile mass are like the shoots of Indian fig tree, *Gunja* or Coral) along with *Pittaj Arsha* symptoms (*Arśas* due to *Pitta*); hence, vitiated *Rakta* (blood) & *Pitta* (*Dosha* responsible for regulating body temperature and metabolic activities) *Dosha* (regulatory functional factors of the body) are dominant in TEH. [3] Whereas, as per modern literature the TEH occurs due increased venous pressure leading to rupture of vein and formation of clot, [2] so keeping the ayurvedic and contemporary perspective in mind the treatment was

planned with *Jalaukaavcharan* (Leeching/Leech Therapy) as in this condition of *Arshas Raktaavsechana* (bloodletting) is indicated by *Acharya Vagbhata* also, [4] it is known that the saliva of *Jalauka* (leech) has bioactive molecules like hirudin, eglin C, bdellins, antistasin, saratin, and complement-C1 inhibitors, which have anticoagulant, anti-inflammatory, analgesic properties, and extracellular matrix-modulating activity, with these properties leeches, have an advantage over the conventional surgical treatment which can be implemented in contraindicated patients with comorbid conditions. As *Jalauka* reduces blood clot, inflammation through its properties, resulting in a significant reduction in acute pain, edema, and stimulated microcirculatory perfusion, which were well supported by previously published clinical outcomes, [5-7] but a biomarker-based assay is still lacking in this context. So, herein we tried to link a gap by doing case-based biomarker analysis supporting the analgesic and anti-inflammatory effect of *Jalaukaavcharan* that offered significant results in the management of TEH.

## 2. CASE REPORT

A 38-year-old male came to the *Shalya Tantra* (Surgery) OPD at KLE Ayurveda Hospital, Belagavi, with severe pain at the anal region, severe tender swelling, anal discomfort in sitting and walking, and unable to pass flatus since 3 days. The patient was nondiabetic, non-hypertensive, with no history of TB, immunosuppression, or previous anorectal surgeries. On initiation of complaints, the patient has taken painkiller medicine from a medical store but didn't get

any pain relief; rather, the pain aggravated. So, for the management of the same patient came to our OPD.

#### a. Clinical findings

Clinical examination of perianal region was done. On inspection, a single dark, congested, reddish purple mass was seen along with other mass lined by skin extending from 6 o'clock to 7 o'clock position, measuring about 4x2 cm in size (Figure 1a) also, a swelling was noted around the mass. On palpation, it was found that the mass was firm, tender, and tense, while the other mass was moderately hard, tender, and the mass was very painful to touch, along with perianal guarding and raised local temperature. DRE (Digital rectal examination) was not done due to severe pain, and the pain assessment was done on Visual Analogue Scale (VAS) which was noted to be 8/10 while Visual Descriptor Scale (VDS) was noted as 8/10. Medical history and family history were not related to the present complaints. Systemic examination was done, and no abnormality was seen in the cardiovascular, respiratory systems. Vitals were taken: BP-142/90 mmHg, Pulse Rate-90 bpm, and blood investigations showed Hb 14.0 g/dl, WBC count 6700 cells/cu mm (Neutrophils 56%, Lymphocytes 33%, Eosinophils 8%, Monocytes 1%), ESR 30mm/1<sup>st</sup> hr, RBS 102 mg/dl, Blood Urea 24 mg/dl, S. Creatinine 1.1 mg/dl, BT, CT, Urine Routine were within normal limits.

The biomarker IL-6 level was quantified as per the Human IL-6 Genlisa™ ELISA kit protocol (Krishgen Biosystems, Lot No: 161224, Catalog No: KB1068) mentioned by manufacturer. The assay was based on

sandwich enzyme - linked immunosorbent assay (ELISA) principle employing double antibody detection. [8]

As per ayurveda it was found that the pile mass was dark red in color resembling the color of *Gunja (Abrus precatorius)/Vidrum* (Moonga stone) along with severe pain, tenderness which are the symptoms of *Pittaj Arsha* as these all are the symptoms found in *Raktaj Arsha*, so the patient was diagnosed with *Raktaj Arsha*.

#### b. Diagnostic Assessment

Inflamed sentinel tag and TEH were considered as differential diagnosis. The diagnosis of TEH was established based on the signs, symptoms, and result of clinical examination. *Shophayukta Chramakeela Arsha, Pittaj Arsha, Raktaj Arsha* were considered for Ayurveda differential diagnosis, where *Raktaj Arsha* was considered as an *Ayurveda* diagnosis because the symptoms of it mimics the clinical features of TEH.

#### c. Intervention

The treatment was planned based on *Dosha* (regulatory functional factors of body) involvement, which causes *Raktaj Arsha* (TEH) and the pathology of TEH. For achieving the same desired treatment plan was explained to the patient, and consent was taken. The treatment indicated, i.e., *Raktaavsechana* for *Raktaj Arsha*, [4] was done via *Jalaukaavcharan*, using one *Jalauka* measuring around 5 to 6 cm in length and 0.7cm in breadth, followed by application of *Haridra Churna* at *Jalauka Dansha Sthana* (leech bite site). The *Jalaukaavcharan* was done as per SOP in TEH for which the patient was taken in the left lateral position, and the TEH was cleaned gently with distilled water followed by application of leech on TEH mass (Figure

1b, 1c). As soon as the leech started sucking the blood its body was covered with a wet gauze piece. The leech fell from the mass after 25 minutes as it stopped blood sucking. The gentle pressure was applied at leech bite site and dressing was done with *Haridra Churna* (*Curcuma longa* powder). In post procedural care the patient was kept under observation and bleeding or oozing of blood from leech bite site was also observed. The 2<sup>nd</sup> session of *Jalaukaavcharan* was done on the 3<sup>rd</sup>

day (after 71 hours of the 1<sup>st</sup> session). In both the sessions of *Jalaukaavcharan* (1<sup>st</sup> & 2<sup>nd</sup>) the leech stopped sucking blood approximately after 25 minutes and fell from the TEH mass. During the treatment the patient was kept under observation, and no complication of bleeding or oozing was seen from the leech bite site.

**d. Timeline (Table. 1)**

**Table no 1: Timeline of the case**

Plan of care	Date	Symptoms	Procedures Performed
Poorva karma	05/05/2025 (Baseline)	Acute thrombosed external hemorrhoids (TEH)	<ol style="list-style-type: none"> <li>Blood samples collected &amp; sent for investigations.</li> <li>Procedure (<i>Jalaukaavcharan</i>) was explained to the patient, &amp; Consent was taken.</li> <li>Vitals recorded- BP: 142/90 mm Hg, PR: 90 bpm, SpO<sub>2</sub>: 99% @ RA</li> <li>Leech prepared (activated) in <i>Haridra</i> water for 5 minutes.</li> </ol>
		VAS- 8/10      VDS- 8/10	
	05/05/2025 (1 hr. before procedure)	Acute TEH	A blood sample was taken to measure the inflammatory marker IL-6.
		VAS- 8/10      VDS- 8/10      IL-6- 15.462 pg/ml	
Pradhan karma	05/05/2025 (during procedure)	Acute TEH	<p><b><i>Jalaukaavcharan</i> was done following the SOP</b></p> <ol style="list-style-type: none"> <li>The thrombosed pile mass was gently cleaned with distilled water.</li> <li>Watched for anchoring of a leech to the pile mass.</li> <li>Leech stopped sucking blood after (≈25 minutes).</li> <li>Vitals recorded: BP: 140/90 mm Hg, PR: 88 bpm, SpO<sub>2</sub>: 98% @ RA</li> </ol>
	07/05/2025	No pain in the anal region on sitting, walking, or during defecation	<p><b><i>Jalaukaavcharan</i> was done following the SOP</b></p> <ol style="list-style-type: none"> <li>The pile mass was gently cleaned with distilled water, and a leech was applied till it stopped sucking blood (≈25 minutes).</li> <li>Vitals recorded:BP: 120/76 mm Hg, PR: 70 bpm,</li> </ol>

				SpO <sub>2</sub> : 98% @ RA	
<b>Paschat karma</b>	05/05/2025 (Immediately after the procedure)	Reduction in pain in the anal region on sitting, walking			<b>Post procedural care</b> 1. After leech falls, gentle pressure is applied and dressing with <i>Haridra Churna</i> . 2. The patient was kept under observation for and bleeding or oozing of blood from leech bite site was also observed. 3. Vitals: BP: 130/80 mm Hg, PR: 80 bpm, SpO <sub>2</sub> : 98% @ RA 4. Leech vomiting was done about 10-15 ml of blood was vomited, and the leech was shifted to a new vessel with clean water.
	05/05/2025 (After 2 hr of procedure)	Mild discomfort in the anal region or difficulty in sitting or walking			
		VAS- 2/10	VDS- 2/10	IL-6- 0 pg/ml	Vitals recorded:(BP: 116/80 mm Hg, PR: 74 bpm, SpO <sub>2</sub> : 99% @ RA)
	05/05/2025 (After 8 hr of procedure)	Mild discomfort in the anal region or difficulty in sitting or walking			Vitals recorded: BP: 120/80 mm Hg, PR: 70 bpm, SpO <sub>2</sub> : 99% @ RA
	07/05/2025	No pain in the anal region on sitting, walking, or during defecation.			<b>Post procedural care</b> 1. After leech falls, gentle pressure is applied and dressing with <i>Haridra Churna</i> . 2. Vitals: BP: 118/76 mm Hg, PR: 70 bpm, SpO <sub>2</sub> : 98% @ RA 3. The patient was kept under observation for and bleeding or oozing of blood from leech bite site was also observed. 4. Leech vomiting was done about 10-15 ml of blood was vomited, and the leech was shifted to a new vessel with clean water
		VAS- 0/10	VDS- 0/10	IL-6- 0 pg/ml	

#### e. Follow-up and outcome

After the 2<sup>nd</sup> session of *Jalaukaavcharan* on the 3<sup>rd</sup> day the patient was discharged as he had stable vitals. At the time of discharge the patient was advised to take

fiber-rich diet and sitz bath with lukewarm water. During the treatment, blood samples were taken three times for the measurement of IL-6 levels (1<sup>st</sup> time: an hour before the procedure i.e. *Jalaukaavcharan* on 1<sup>st</sup> day, 2<sup>nd</sup>

time: 2 hours after the procedure on 1<sup>st</sup> day, 3<sup>rd</sup> time: after the procedure on 3<sup>rd</sup> day). The assessment of presenting complaints was done during the treatment, like Pain through VAS, VDS scale, Itching, anal discomfort and passing of flatus. His presenting complaints made it difficult for him to do his daily work,

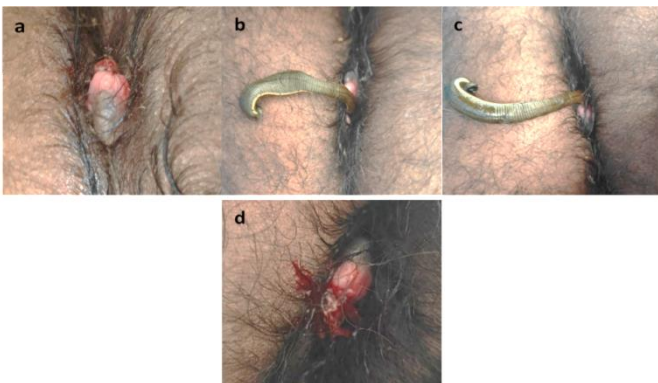affecting his quality of life (QoL), so for assessment of the same, he was assessed via the EQ-5D-5L (QoL) questionnaire during the admission period. No adverse effects were noted during or after the leech therapy. (Table. 2)

**Table 2: Follow-up and outcome**

Parameters		0th Day		3rd Day
		Baseline	2 hour post- treatment	After leech therapy
Pain	VAS	8/10	2/10	0/10
	VDS	8/10	2/10	0/10
Tenderness #(STTGS)		Grade 3	Grade 1	Grade 0
Itching		Mild	Absent	Absent
Localised swelling		++	+	-
Anal discomfort on walking/sitting		+	-	-
Flatus		Unable to Pass	Passed	Passed
Biochemical Indicator (IL-6)		15.462 pg/mL	0 pg/mL	0 pg/mL
<b>EQ-5D-5L (QoL) Questionnaire</b>				
<b><u>MOBILITY</u></b>				
1. I have no problems in walking about.				
2. I have slight problems in walking about.		4	1	1
3. I have moderate problems in walking about.				
4. I have severe problems in walking about.				
5. I am unable to walk about.				
<b><u>SELF-CARE</u></b>				
1. I have no problems washing or dressing myself.				
2. I have slight problems washing or dressing myself.		4	1	1
3. I have moderate problems washing or dressing myself.				
4. I have severe problems washing or dressing myself.				
5. I am unable to wash or dress myself.				
<b><u>USUAL ACTIVITIES</u></b>				

<b>(e.g. work, study, housework, family or leisure activities)</b> 1. I have no problems doing my usual activities. 2. I have slight problems doing my usual activities. 3. I have moderate problems doing my usual activities. 4. I have severe problems doing my usual activities. 5. I am unable to do my usual activities	5	2	1
<b><u>PAIN / DISCOMFORT</u></b> 1. I have no pain or discomfort. 2. I have slight pain or discomfort. 3. I have moderate pain or discomfort. 4. I have severe pain or discomfort. 5. I have extreme pain or discomfort	4	2	1
<b><u>ANXIETY / DEPRESSION</u></b> 1. I am not anxious or depressed. 2. I am slightly anxious or depressed. 3. I am moderately anxious or depressed. 4. I am severely anxious or depressed. 5. I am extremely anxious or depressed	5	2	1
<b>Summary:</b> EQ-5D-5L Index value, calculated using India value set (0.949 max, -0.596 min)	-0.152 (very poor health)	0.835 (Large improvement; near-normal quality of life)	1.000 (no problems in any dimension)

\*Soft tissue tenderness grading scheme



**Figure 1:** Therapeutic Intervention (a) Before intervention on 0<sup>th</sup> day, (b) During the Jalaukaavcharana on 0<sup>th</sup> day, (c) During the Jalaukaavcharana on 3<sup>rd</sup> day, (d) After the Jalaukaavcharana procedure

### 3. DISCUSSION

Present case report confirmed a substantial decrease in anal pain, swelling along with biomarker level suggesting analgesic and anti-inflammatory effect of *Jalaukaavcharan* in Thrombosed hemorrhoids corresponding with the therapeutic goals of the intervention. These clinical outcomes correlate with prior studies but lacks biomarker inclusion in the analysis. [9] So, IL-6 biomarker analysis makes the

present study distinctive and provides robust, objective evidence of pharmacological (thrombolytic/anti-inflammatory) effects. *Jalaukaavcharan* is well accepted due to its noninvasive nature, on the other hand, the conventional surgical procedures are seen to be associated with complications resulting in patient hesitancy due to fear of surgery, cost, and cultural factors. [10] *Jalaukaavcharan* is a type of *Visravan karma* (drainage therapy) explained for *Arshas* having *Laxanas* (signs) like *Nirgattani* (prolapsed), *Doshapurnani* (vitiating *doshas*), which are correlated to *Raktaj Arsha* with dominance of vitiating *Pitta*, *Rakta Pradhan Doshas* (*Pitta* & *Rakta* predominant) and *Dushya* (any bodily structure that gets vitiating by aggravated *Dosha*) as *Twak* (skin), *Mamsa* (muscle tissue). So *Raktaavsechana* was planned as it is indicated for a disease in which *Doshas* are situated in *Twak* also, [11] the sucked-out blood by *Jalauka* is believed to carry toxins in the form of vitiating *Rakta* and *Pitta Doshas* serving to purify the blood with its *Sheeta* (cooling), *Madhura gunas* (Sweet qualities), pacifying the vitiating *Doshas* (Flow diagram. 1,2) and relieving the symptoms in thrombosed piles. [12] It reduces the congestion and enhances microcirculation at the site, which helps to alleviate the local inflammation. As the IL-6 levels reduced from 15.462pg/ml at baseline to 0 pg/ml after the 1<sup>st</sup> session of *Jalaukaavcharan*, this provides concrete evidence of reduction in pain, which occurred due to decongestion in hemorrhoids caused by the thrombolytic activity, anticoagulant property, thrombin regulatory function, and extracellular matrix degradation properties

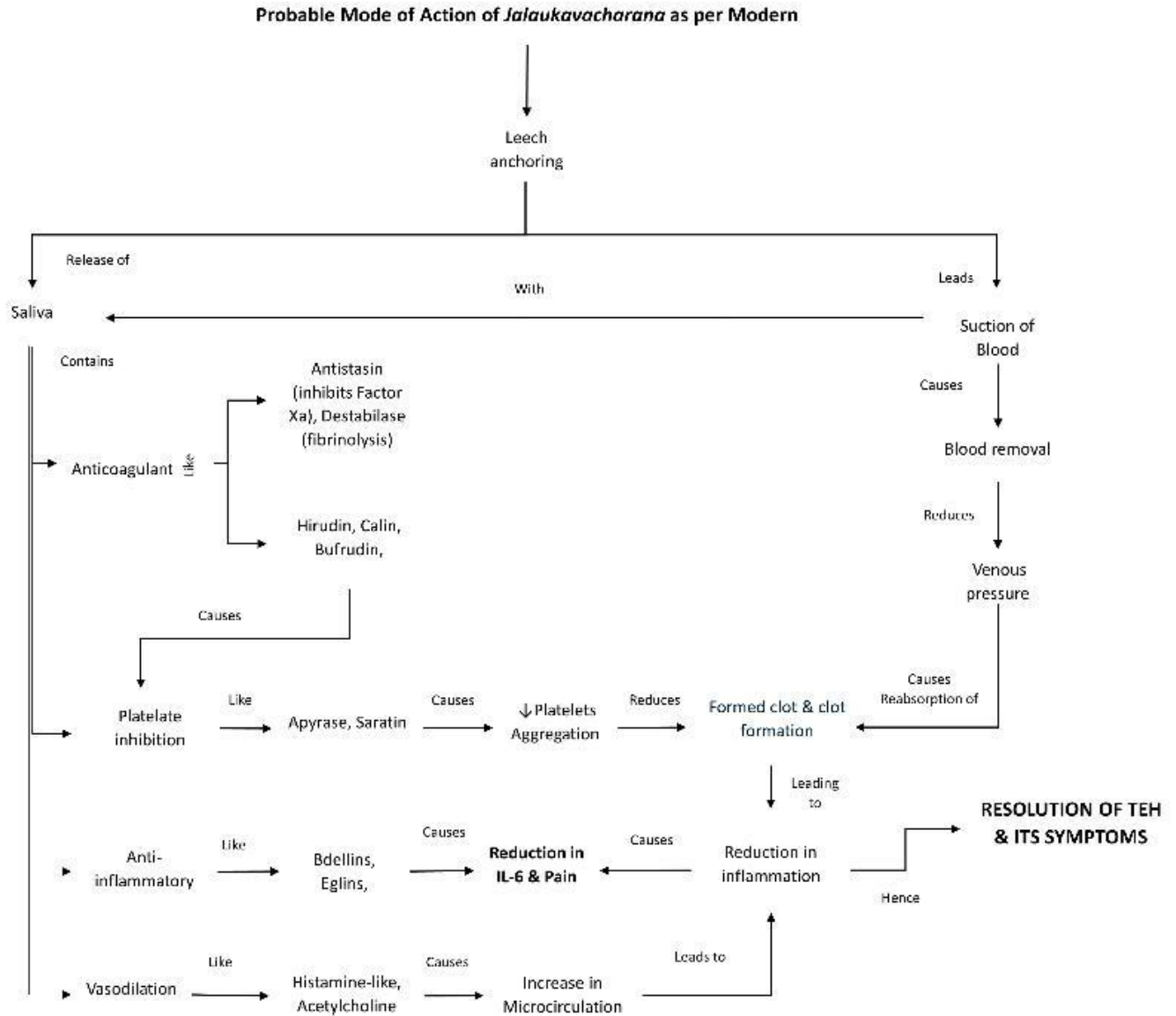
exhibited by the chemicals found in leech saliva. *Jalauka* also increases microcirculation at its bite site by sucking the blood. As IL-6 tends to attain its peak level by the 3<sup>rd</sup> day, it then increases or is maintained till the 7<sup>th</sup> day, but in the present case it was found that the IL-6 levels were not raised or had fluctuated after 2<sup>nd</sup> hour of 1<sup>st</sup> session of *Jalaukaavcharan* till 69 hours (2<sup>nd</sup> session of *Jalaukaavcharan*) that signifies the effect of *Jalaukaavcharan*. At the same time, the analgesic and anti-inflammatory property exhibited by leeches is due to presence of various bioactive molecules like Hirustasin, Eglin C, Bdellins, Guamerin, etc., present in its saliva which acts on pain pathways at different levels also the leech bite modulates the perception of pain in patients which corresponds to the gate control theory. [13-15] Saliva containing an anesthetic effect also adds to the analgesic action, along with inactivation of Kinin, inhibition of neutrophil elastase affecting the inflammation, and blockade of the kinin-kallikrein system, etc., resulting in the quick reduction of pain and inflammation. [16] Clinically, the patient's QoL improved as psychological comfort was achieved by its noninvasive nature, and due to the reduction in pain, inflammation after the procedure, leading to relaxation of the anal muscles, enabling him to pass flatus, resulting in early restoration of the patient's activity.

Without any surgical intervention, all the symptoms of the patient were completely resolved by the 3<sup>rd</sup> day. This provides evidence that the *Ayurvedic* Para surgical procedures have a potential for integration into modern proctologic care as a first line of minimal noninvasive

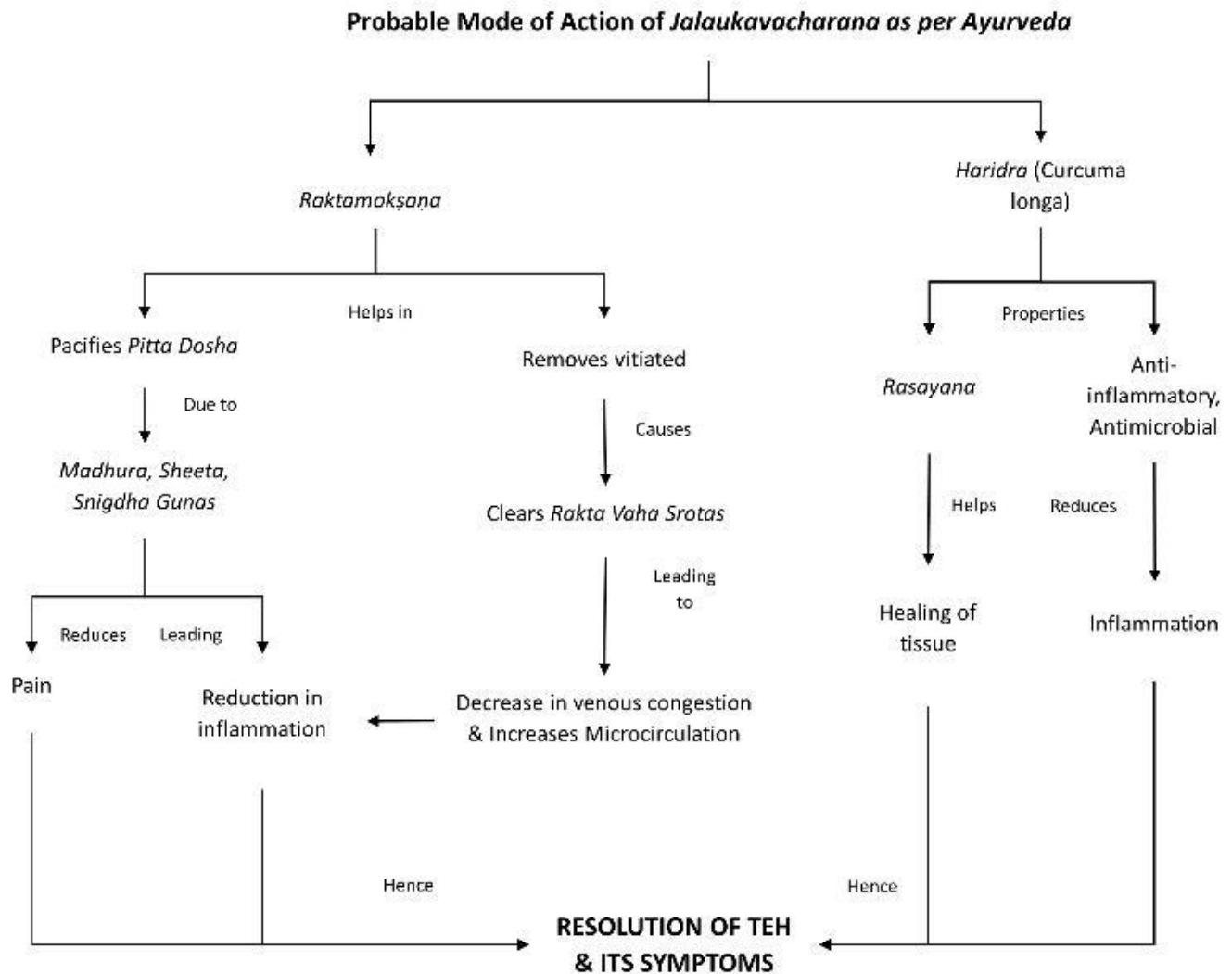
approach in the management of such acute painful conditions like TEH.

This is a single case report having a short-term follow-up and a single biomarker assessment (IL-6 only), so

larger controlled studies are warranted to generalize the findings of this case report.



**Flow diagram 1: Probable Mode of Action of *Jalaukaavcharana* in *Raktaj Arsha* (Thrombosed hemorrhoids) as per Modern**



**Flow diagram 2: Probable Mode of Action of *Jalaukaavcharan* in *Raktaj Arsha* (Thrombosed hemorrhoids) as per Ayurveda**

#### 4. CONCLUSION

Thrombosis in hemorrhoids is an acute condition requiring immediate treatment, the same was seen in the present case, as the patient was suffering from the TEH from the past 3 days which was treated on the Ayurvedic principle of *Rakataavsechana* via *Jalaukaavcharan* for the 3 days, during which two sessions of *Jalaukaavcharan* were done in the present case. The *Jalaukaavcharan* in this

case resulted in complete resolution of all the symptoms by the 3<sup>rd</sup> day and resulted in a reduction of IL-6 levels, which proves its analgesic, anti-inflammatory effects. Hence, this case provides data for the clinical validity of *Jalaukaavcharan* in thrombosed hemorrhoids, as a successful outcome has been achieved in this case with no adverse events observed during and after the treatment in the follow up period

of 2 weeks. Also, it is to be noted that it can be used in high-risk patients or patients not opting for surgery.

**Abbreviations:** TEH (Thrombosed External Hemorrhoids), VAS (Visual Analogue Scale), VDS (Visual Descriptor Scale), BT (Bleeding time), CT (Clotting time), SOP (Standard operating procedure), IL-6 (Interleukin-6), STTGS (Soft tissue tenderness grading scheme)

**Declaration of Patient Consent** – The authors confirm that they have acquired a patient consent form, in which the patient or caregiver has granted permission for the publication of the case, including accompanying images and other clinical details, in the journal. The patient or caregiver acknowledges that their name and initials will not be disclosed, and sincere attempts will be undertaken to safeguard their identity. However, complete anonymity cannot be assured.

**Patient perspective** - I was having severe pain from the last 3 days when I visited here. I also took medicines from a medical store near my home, but it hasn't relieved my pain. The day I came to you, my pain was so severe that I could not sit or walk properly; also I wasn't able to pass flatus, so I had to take leave from my work schedule. As I was scared of surgery the doctor explained to me about my condition and treatment plan, which gave me a lot of emotional support. Today I am completely fine with no pain or problem in sitting and walking, also I can pass flatus now. I want to thank all the doctors for their emotional support and care.

**Authors Details:**

<sup>1\*</sup> Associate Professor, Department of Shalya Tantra, KLE Academy of Higher Education and Research, Deemed to be University, KAHER's Shri B M Kankanwadi Ayurveda Mahavidyalaya, Shahpur Belagavi, Karnataka, India.

<sup>2</sup>PG Scholar, Department of Shalya Tantra, KLE Academy of Higher Education and Research, Deemed to be University, KAHER's Shri B M Kankanwadi Ayurveda Mahavidyalaya, Shahpur Belagavi, Karnataka, India.

<sup>3</sup>Assistant Professor, SRI SAI Ayurvedic PG Medical College & Hospital, Sarsol, Aligarh, U.P: 202001

**Authors Contribution:**

Conceptualization and Clinical Management: All Authors.

Data collection and literature search: Dr SYM, Dr RJ

Writing Original Draft: Dr RJ, Dr UG

Reviewing & Editing: Dr UG, Dr SYM.

Approval of Final Manuscript: All the Authors.

**Declaration of Generative AI**

The authors declare this manuscript was written without the use of generative artificial intelligence tools. All the content, including text generation, data analysis and references was developed and reviewed by the author without assistance from AI technologies.

**Conflict of Interest** – The authors declare no conflicts of interest.

**Source of Support** – The authors declare no source of support.

**Additional Information:**

Authors can order reprints (print copies) of their articles by visiting:

<https://www.akinik.com/products/2281/journal-of-ayurveda-and-holistic-medicine-jahm>

**Publisher's Note:**

Atreya Ayurveda Publications remains neutral with regard to jurisdictional claims in published maps, institutional affiliations, and territorial designations. The publisher does not take any position concerning legal status of countries, territories, or borders shown on maps or mentioned in institutional affiliations.

**REFERENCES:**

1. Stanojević G, Branković B, Nestorović M, Milutinović N. Surgical treatment of hemorrhoidal disease [Internet]. Anorectal Disorders - From Diagnosis to Treatment. IntechOpen; 2023 Nov. Available from: <http://dx.doi.org/10.5772/intechopen.1002738>
2. Picciariello A, *et al.* Management and Treatment of External Hemorrhoidal Thrombosis. *Frontiers in Surgery*. 2022 May;9. Available from: <https://doi.org/10.3389/fsurg.2022.898850>
3. Ambikadutta Shastri (editor). Commentary: Ayurveda Tattva Sandipika on Susruta Samhita of Maharsi Susruta, Nidanasthana, chapter 2, verse no. 14, 12th edition, Varanasi; Chaukhambha Sanskrit Sansthan;2001;238
4. Brahmanand Tripathi (editor). Commentary: Nirmala on Ashtanga Hrdayam of Srimadvagbhata, Chikitsasthana, chapter 8, verse no. 28, reprint, Delhi; Chaukhambha Sanskrit Pratishthana;2003;660
5. Bhagat P, Raut S, Lakhapati A. Clinical efficacy of Jalaukawacharana (leech application) in Thrombosed piles.

- AYU. 2012 Apr-Jun;33(2):261-263. Available from: <https://doi.org/10.4103/0974-8520.105248>
6. N Divya Sravani, K V Vijaya Bhaskara Reddy. Role of Jaloukavacharana in Management of Raktharshas (Thrombosed Hemorrhoids). International Journal of Ayurveda and Pharma Research (IJAPR). 2022 Aug; 10(8): 90-93. Available from: <https://doi.org/10.47070/ijapr.v10i8.2479>
  7. Afroz AT, Najar FA, Faisal M, Fatima M. Effect of Irsale Alaq (leech therapy) in thrombosed pile mass: a case study. International Journal of Scientific Reports. 2020 Jun;6(6):220-222. Available from: <https://doi.org/10.18203/issn.2454-2156.intjsci20202098>
  8. Krishgen Biosystems – Krishgen Biosystems – Our Reagents Your Research. Human IL-6 GENLISA™ELISA. Available from: [https://www.krishgen.com/upload/datasheets/Lyophilized\\_2021\\_KIT\\_INSERT\\_KB1068\\_Human\\_IL-6\\_Ver\\_6-2.pdf](https://www.krishgen.com/upload/datasheets/Lyophilized_2021_KIT_INSERT_KB1068_Human_IL-6_Ver_6-2.pdf)
  9. Lohsiriwat V. Treatment of hemorrhoids: A coloproctologist's view. World Journal of Gastroenterology (WJG). 2015 July;21(31):9245-9252. Available from: <https://doi.org/10.3748/wjg.v21.i31.9245>
  10. Tavani ME, Partovi Y, Poursaki T, Gharibi F. The Complications of Hemorrhoidectomy From Patients' Perspective: A Qualitative Study. Health Science Reports. 2025 Apr;8(5):1-14. Available from: <https://doi.org/10.1002/hsr2.70724>
  11. Ambikadutta Shastri (editor). Commentary: Ayurveda Tattva Sandipika on Susruta Samhita of Maharsi Susruta, Sutrasthana, chapter 14, verse no. 34, 12th edition, Varanasi; Chaukhambha Sanskrit Sansthan;2001;54
  12. Ambikadutta Shastri (editor). Commentary: Ayurveda Tattva Sandipika on Susruta Samhita of Maharsi Susruta, Chikitsasthana, chapter 13, verse no. 6, 12th edition, Varanasi; Chaukhambha Sanskrit Sansthan;2001;43
  13. Sig AK, Guney M, Uskudar Guclu A, Ozmen E. Medicinal leech therapy—an overall perspective. Integrative Medicine Research. 2017 Dec;6(4):337-343. Available from: <https://doi.org/10.1016/j.imr.2017.08.001>
  14. Baskova IP, Zavalova LL, Basanova AV, Moshkovskii SA, Zgoda VG. Protein Profiling of the Medicinal Leech Salivary Gland Secretion by Proteomic Analytical Methods. Biochemistry (Moscow). 2004 Jul;69(7):770-5. Available from: <https://doi.org/10.1023/b:biry.0000040202.21965.2a>
  15. Nowak G, Schrör K. Hirudin – the long and stony way from an anticoagulant peptide in the saliva of medicinal leech to a recombinant drug and beyond. Thromb Haemost. 2007 May;98(07):116-119. Available from: <https://doi.org/10.1160/th07-05-0364>
  16. IP Baskova, S Kalil, GI Nikonov, SE Rabinovich, VF Nartikova. Inhibition of kallikrein from human plasma by salivary gland secretion and extracts of the medicinal leech *Hirudo medicinalis*. PubMed. 1988 Sep;53(9):1467-73. Available from: <https://pubmed.ncbi.nlm.nih.gov/3203110/>